

## Protective effect of *Solanum torvum* on monosodium glutamate-induced hepatotoxicity and nephrotoxicity in rats

Vrushali Kadam, Sushilkumar Gangurde and Mahalaxmi Mohan\*  
M.G.V's Pharmacy College, Panchavati, Nasik, Maharashtra 422003, India

Received 31 August 2017; Revised 24 January 2019

The objective of the study was to determine the protective effect of *Solanum torvum* on Monosodium glutamate (MSG) induced hepatotoxicity and nephrotoxicity in rats. Wistar rats received MSG (1000 mg/kilogram, per oral) followed by methanolic and hydroalcoholic extracts of *S.torvum* (100 & 300 mg/kg, p.o.) respectively for 14 days. Percentage change in body weight, relative organ weight of liver and kidney, liver function tests, kidney function tests and histopathological studies of liver and kidney tissues were observed in rats. *In vitro* antioxidant activity of *S.torvum* extracts was also performed. The results were analysed by One-way ANOVA followed by Dunnett's test. The msg-treated group showed significant ( $p < 0.05$ ) increase in percentage change in body weight, relative organ weight of liver and kidney and lipid peroxidation, a significant decrease in SOD activity in liver and kidney tissue and a significant change in hepatic and renal marker enzymes, as compared to control group. While treatment with *S. torvum* extracts ameliorated the effects induced by MSG group. Total flavonoid content of methanolic & hydroalcoholic extract of *S. torvum* was found to be  $44 \pm 1.2$  &  $32 \pm 0.8 \mu\text{g}$  of rutin equivalent/mg of extract and total phenolic content was found to be  $70 \pm 0.28$  &  $52 \pm 0.62 \mu\text{g}$  of gallic acid equivalent/mg of extract respectively. *In vivo* and *In vitro* antioxidant studies of both extracts showed that methanolic extract has more hepatoprotective, nephroprotective and anti-oxidant property than the hydroalcoholic extract of *S.torvum* fruits. It is concluded that *S.torvum* extract has a protective effect against MSG-induced hepatic and renal toxicity.

**Keywords:** Hepatotoxicity, Monosodium glutamate, Nephrotoxicity, Oxidative stress, *Solanum torvum*.

**IPC code; Int. cl. (2015.01)**-A61 K36/00, A61 P 1/00

### Introduction

Toxicity is any harmful effect of a chemical or a drug on a target organ<sup>1</sup>. Nephrotoxicity is a poisonous effect of some substances, both toxic chemicals and medication on the kidneys while hepatotoxicity implies chemical-driven liver damage. Since the kidney is involved in the excretion of many toxic metabolic waste products, particularly the nitrogenous compounds and the liver is also involved in many metabolic processes<sup>2</sup>, damage to these organs results in disturbances in metabolism.

Monosodium glutamate (MSG) is the sodium salt of glutamic acid<sup>3</sup>. Trade names of monosodium glutamate include ajinomoto, vetsin, accent and tasting powder<sup>4</sup>. Monosodium glutamate contains 78% glutamic acid, 22% sodium and water<sup>5</sup>. Glutamate is one of the most common amino acids found in nature and is the main component of many proteins and peptides of most tissues<sup>6</sup>. Glutamate is also produced in the body and plays an essential role in human metabolism. It is a major component of many

protein-rich food products either in a free or bound state of an animal such as meat, fish, milk and cheese or vegetable origins such as mushroom and tomato<sup>7</sup>. MSG is one of the commonest food additives. It has been used as taste enhancer since 1907 by a Japanese professor<sup>8</sup>.

MSG is known to have some adverse effect i human and experimental animals. These include the Chinese restaurant syndrome<sup>9</sup>, neuroexcitotoxicity<sup>10</sup>, obesity<sup>11</sup>, impaired vision<sup>12</sup>, burning sensation of different parts of the body, headache, chest pain, flushing, sweating, nausea or vomiting<sup>13</sup>. Monosodium glutamate is absorbed very quickly from the gastrointestinal tract and could spike blood plasma level of glutamate. Glutamate is the most abundant amino acid in the central nervous system where it functions as an excitatory neurotransmitter<sup>14</sup>.

Vitamins have an indispensable role in almost all biochemical reactions and they are ideal antioxidants able to increase tissue protection from oxidative stress due to their easy, effective and safe dietary administration in a large range of concentrations<sup>10</sup>. Antioxidant vitamins play an important role in the

\*Correspondent author  
Email: mm\_nasik@yahoo.co.in  
Mob: 9731270123

regulations of various physiological and pathological processes. Vitamin C (L-ascorbic acid) is one of the most important non-enzymatic radical scavengers present in *in-vivo* cellular aqueous compartment. Vitamin C, as a water-soluble antioxidant is reported to equalize ROS and minimize oxidative DNA damage and hence genetic mutations<sup>15,16</sup>.

*Solanum torvum* Sw. (Solanaceae), commonly known as Turkey berry is an erect spiny shrub of about 4m tall, evergreen and widely branched. It is native and found cultivated in Africa and West Indies<sup>17</sup>. The fruits and leaves are widely used in Cameroonian folk medicine. The plant is cultivated in the tropics for its sharp tasting immature fruits. It is used in the treatment of stomach pain and skin infections<sup>18</sup>. *Solanum torvum* possesses antimicrobial<sup>19,20</sup>, antiviral<sup>21</sup>, immuno-secretory<sup>22</sup>, antiulcer<sup>23</sup>, antioxidant<sup>24,25</sup>, analgesic and anti-inflammatory<sup>26</sup> activities in animal models. Mohan and co-workers studied cardio-protective<sup>27</sup>, hepatoprotective<sup>28</sup> and nephroprotective<sup>29</sup> activity against doxorubicin-induced toxicities in Wistar rats and antihypertensive and metabolic correction activity in fructose hypertensive rats<sup>30</sup>. The immunomodulatory and antioxidant property of the plant may be used in the treatment of benign prostatic hyperplasia<sup>31</sup>. Phytochemical studies reveal the presence of many compounds such as 2,3,4-trimethyltriacontane, 5-hexacontane, triacontanol, 3-tritriacontane, tetratriacontane acid, sitosterol, stigmaterol, campesterol, neochlorogenin 3-O- $\beta$ -L-rhamnopyranosyl,  $\beta$ -L-rhamnopyranoside, chlorogene, neochlorogenone<sup>32</sup>. Isoflavonoidsulfate and steroidal glycosides<sup>33</sup>. Nine known compounds including neochlorogenin 6-O- $\beta$ -D-quinovopyranoside, neochlorogenin 6-O- $\beta$ -D-xylopyranosyl-(1 $\rightarrow$ 3)- $\beta$ -D-quinovopyranoside, neochlorogenin 6-O- $\alpha$ -L-rhamnopyranosyl-(1 $\rightarrow$ 3)- $\beta$ -D-quinovopyranoside, solagenin 6-O- $\beta$ -D-quinovopyranoside, solagenin 6-O- $\alpha$ -L-rhamnopyranosyl-(1 $\rightarrow$ 3)- $\beta$ -D-quinovopyranoside, isoquercetin, rutin, kaempferol and quercetin were isolated from *S. torvum*<sup>34</sup>. Solasodine, solasonine and solamargine are the glycoalkaloids identified from total alkaloids of leaves of *S. torvum*<sup>35</sup>. A new C4-sulfated isoflavonoid [torvanol A] and steroidal glycoside [torvoside H] together with torvoside A isolated from a methanolic extract of *S. torvum* fruits exhibited antiviral activity<sup>21</sup>. The biological activity of dietary flavonoids has been attributed to their antioxidant activity<sup>36</sup>.

MSG is reported to be hepatotoxic and nephrotoxic in experimental animals when combined with food<sup>37</sup>

and administered by oral intubation<sup>38,39</sup>. Studies have revealed that increased plasma concentration of glutamate can cause chronic renal damage, such as ischemia, toxic injury and renal cell carcinoma. Glutamate occupies a central role in hepatic amino acid metabolism according to its function of transamination and catabolism of most amino acids<sup>40</sup>. However, a few studies have revealed that the injection of exogenous glutamate can lead to the development of significant liver inflammation<sup>41</sup>. MSG-induced hepatic and renal damage is mainly due to increased oxidative stress and a decline in antioxidant defence mechanism. Many animal studies showed that the extent of toxicity of MSG mainly depends on a few factors like the route of administration, the age of experimental animals and dose of MSG<sup>42</sup>. Many of phytochemicals and herbal formulations are being investigated for their hepatoprotective and nephroprotective properties. In view of the above literature *S. torvum*, a commonly used food condiment has not been tapped for its potential to reverse MSG-induced organ toxicities. Therefore the present study has been aimed to study the effect of methanolic and hydroalcoholic extract of *S. torvum* against MSG-induced hepatotoxicity and nephrotoxicity.

## Materials and Methods

### Extract preparation

Dry seeds of *S. torvum* were purchased locally, authenticated by Dr. Shishir Pande from Ayurveda Sanshodhan Vibhag, Nashik where the specimen has been deposited (Voucher No-ASS962). Seeds were crushed into fine powder. The powdered material (250 g) was first defatted with petroleum ether (60-80 °C) using Soxhlet apparatus (Model no 3840029, Borosil). The marc was dried and again extracted using methanol and hydroalcoholic (methanol and water; 70:30) solvents. The methanolic and hydroalcoholic extracts of *S. torvum* were air-dried to obtain the product (ST-ME: 12.61 % w/w and ST-HOH: 10.76 % w/w respectively).

### Determination of In-Vitro Antioxidant Activity

#### Determination of Total Phenolic Contents in *S. torvum* extracts

The total phenolics content of the plant extracts was determined using the spectrophotometric method (UV-2450, Shimadzu). A methanolic solution of the ST-ME and ST-HOH in the concentration of 1 mg/mL was used. The reaction mixture was prepared by mixing 0.5 mL of a methanolic solution of extract, 2.5 mL of 10% Folin-Ciocalteu's reagent dissolved in

water and 2.5 mL 7.5 % NaHCO<sub>3</sub><sup>43</sup>. Blank was concomitantly prepared, containing 0.5 mL methanol, 2.5 mL 10 % Folin-Ciocalteu's reagent dissolved in water and 2.5 mL of 7.5 % of NaHCO<sub>3</sub>. The samples were thereafter incubated in a thermostat at 45 °C for 45 minutes. The absorbance was determined using spectrophotometer at λ<sub>max</sub> at 765 nm. The samples were prepared in triplicate and the mean value of absorbance was recorded. The same procedure was repeated for the standard solution of gallic acid for the calibration curve. Based on the measured absorbance, the concentration of phenolics was observed as (mg/mL) from the calibration line. The equivalent content of phenolics in *S.torvum* extract was expressed in terms of gallic acid equivalent (mg of GA/g of extract)<sup>43</sup>.

#### **Determination of flavonoid concentrations in *S. torvum* extracts**

The total flavonoid content was determined in plant extracts using spectrophotometric method (UV-2450, Shimadzu). The sample contained 1 mL of a methanol solution of the ST-ME and ST-HOH in the concentration of 1 mg/mL and 1 mL of 2 % AlCl<sub>3</sub> solution dissolved in methanol. The samples were incubated for an hour at room temperature. The absorbance was determined using spectrophotometer at λ<sub>max</sub> at 415 nm. The samples were prepared in triplicate for each analysis and the mean value of absorbance was obtained. The same procedure was repeated for the standard solution of rutin and the calibration line was constructed. Based on the measured absorbance, the concentration of flavonoids was read (mg/mL) on the calibration line; then, the content of flavonoids in extracts was expressed in terms of rutin equivalent (mg of rutin/g of extract)<sup>44</sup>.

#### **Animals**

Laboratory bred Wistar albino rats of either sex weighing between 160-220 gm, maintained under standard laboratory conditions of 25 ±1°C, and photo period (12 h dark/12 h light) were used for the experiment. Commercial pellet diet (Jay Trading Co. Panchavati, Nashik, India.) and water were provided *ad libitum*. The experiments were carried out according to the guidelines of the Committee for the Purpose of Control and Supervision of Experiments on Animals (CPCSEA), New Delhi, India, and approved by the Institutional Animal Ethical Committee.

#### **Chemicals**

Monosodium glutamate MSG (Sigma-aldrich), Vitamin-C (Research- lab, Mumbai). All chemical

reagents were of analytical grades and purchased from Sigma Chemicals (St. Louis, MO, USA). Biochemical Kits for Alanine Aminotransferase (ALAT or SGPT), Aspartate Aminotransferase (ASAT or SGOT), Alkaline Phosphatase (ALP), Total Protein, Albumin, Bilirubin, Urea, Creatinine were obtained from Sweety Surgicals, Nashik.

#### **Experimental Design**

Animals were divided into 7 groups of 6 animals each and treated for 14 days.

Group I received with MSG (1000mg/kg,p.o.) daily; Group II received distilled water (10 mL/kg, p.o.) daily. Group III received ascorbic acid (Vit-C 0.3 mg/kg, p.o.) and MSG (1000 mg/kg,p.o.) daily. Group IV received with ST-ME (100 mg/kg, p.o.) and MSG (1000 mg/kg, p.o.)daily. Group V received ST-ME (300 mg/kg, p.o.) and MSG (1000 mg/kg, p.o.) daily. Group VI received ST-HOH (100 mg/kg, p.o.) and MSG (1000 mg/kg, p.o.) daily. Group VII received ST-HOH (300 mg/kg, p.o.) and MSG (1000 mg/kg,p.o.) daily.

#### **Percentage change in Body weight, relative liver and relative kidney weight**

Body weight of each animal was determined before treatment and before sacrifice. Liver and kidney tissue of each animal were dissected out and weighed.

#### **Preparation of Serum and Tissue homogenate**

The animals were sacrificed 24 h after the 14 days treatment. Blood samples were withdrawn by cardiac puncture. Serum was separated by centrifugation at 3000 rpm for 10 min. The serum sample was maintained at (-20 °C) to be used for measurement of liver function tests and kidney function tests. A known amount of tissue (Liver & Kidney) was weighed and homogenized in ice-cold 0.1 M Tris-HCl buffer for estimation of SOD and lipid peroxidation activity.

#### **Antioxidant Parameters**

##### ***Superoxide dismutase activity (SOD)***

The assay of SOD was based on the ability of SOD to inhibit spontaneous oxidation of adrenaline to adrenochrome.0.05 mL supernatant was added to 2.0 mL of carbonate buffer and 0.5 mL of 0.01 Mm EDTA solution. The reaction was initiated by addition of 0.5 mL of epinephrine and autoxidation of adrenaline to adrenochrome was measured at 480 nm. The change in absorbance for every minute was measured against blank. The results were expressed as unit of SOD activity (mg/wet tissue)<sup>45</sup>.

### Lipid peroxidation (LPO)

Homogenate (0.1 mL) (Tris-HCl buffer, pH-7.5) was treated with 2 mL of (1:1:1 ratio) TBA-TCA-HCl reagent (Thiobarbituric acid 0.37%, 0.25 N HCl and 15% TCA) and placed in water bath for 15 min, cooled and centrifuged at room temperature for 10 min at 1000 rpm. The absorbance was measured at 535nm<sup>46</sup>.

### Biochemical Assays

#### Assessment of Liver Function tests

##### Aspartate Aminotransferase (ASAT or SGOT)

SGOT catalyses the transfer of amino group between L-Aspartate & Ketoglutarate to form Oxaloacetate & glutamate. The Oxaloacetate formed reacts with NADH in the presence of malate dehydrogenase (MDH) to form NAD<sup>+</sup><sup>47</sup>.

##### Alanine Aminotransferase (ALAT or SGPT)

The amino group between L-Alanine & Ketoglutarate is transferred by SGPT to form Pyruvate & glutamate. The Pyruvate formed, in the presence of MDH reacts with NADH to form NAD<sup>+</sup><sup>47</sup>.

##### Alkaline Phosphatase (ALP)

At pH 10.3 Alkaline Phosphate (ALP) catalyzes the hydrolysis of colourless p-Nitrophenyl phosphate (pNPP) to yellow coloured p-Nitrophenol and phosphate. Change in absorbance due to the yellow colour formation is measured kinetically at 405 nm and proportional at ALP activity in the sample<sup>48</sup>.

##### Total Protein

The peptide bonds of proteins react with cupric ions in alkaline solution to form a coloured chelate, the absorbance of which is measured at 578 nm. The biuret reagent contains sodium-potassium tartrate, which helps in maintaining solubility of this complex at alkaline pH. The absorbance of the final colour is proportional to the concentration of total protein in the sample<sup>48</sup>.

##### Albumin

At pH 3.68, albumin acts as a cation and binds to the anionic dye bromocresol green [BCG], forming a green coloured complex. The absorbance of the final colour is measured at 630 nm. The colour intensity of the complex is proportional to albumin concentration in sample<sup>48</sup>.

##### Bilirubin

Bilirubin reacts with diazotized sulphanilic acid to form coloured azobilirubin compound. The unconjugated bilirubin couples with the sulphanilic acid in presence of a caffeine-benzoate accelerator. The intensity of the colour formed is directly proportional to the amount of bilirubin present in the sample<sup>49</sup>.

### Assessment of Kidney Function tests

#### Urea

Urea reacts with hot acidic diacetylmonoxime in presence of thiosemicarbazide and produces a rose purple coloured complex, which is measured colorimetrically<sup>50</sup>.

#### Creatinine

Creatinine forms an orange coloured complex with picric acid in an alkaline medium. The intensity of the colour formed within a fixed time is directly proportional to the amount of creatinine present in the sample<sup>51</sup>.

### Histopathological examination

Soon after the sacrifice of the animal the liver and kidney tissues were removed immediately and fixed in 10% formalin solution and sent for histopathological examination. These tissues were embedded in paraffin wax, cut into fine thin sections of 3-5µm thickness and were stained with hematoxyline-eosin and observed for histological changes by taking photograph under 40X magnification.

### Statistical analysis

The results were expressed as mean ± SEM. Statistical analysis was done using one-way analysis of variance, followed by Dunnett's multiple comparison tests.  $p < 0.05$  was considered significant<sup>52</sup>.

## Results

### In vitro antioxidant activity

Total flavonoid content was found to be 32±0.8µg of rutin equiv. per mg of hydroalcoholic extract and 44±1.2 µg of rutin equiv. per mg of methanolic extract of *S.torvum* (Fig. 1). Similarly, the total phenolic content was found to be 55±0.62µg of gallic acid equiv. per mg of ST-HOH and 70±0.28 µg of gallic acid equiv. per mg of ST-ME (Fig. 2). This proved that the methanolic extract has better antioxidant activity as compared to the hydroalcoholic extract of *S. torvum*.

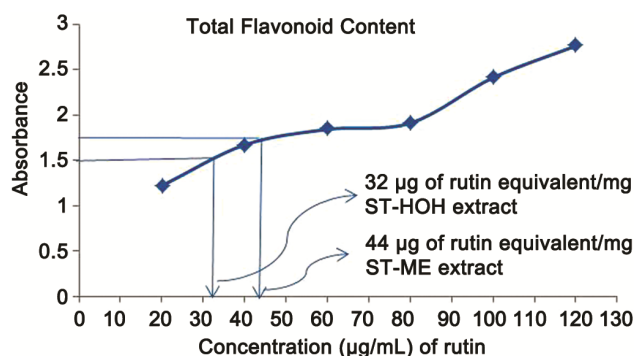


Fig. 1 — Total flavonoid content determination in ST-ME and ST-HOH by AlCl<sub>3</sub> method.

### Percentage change in body weight, relative liver and relative kidney weight

#### Percentage change in body weight

There was a significant ( $p < 0.05$ ) increase in body weight in rats given MSG treatment as compared to vehicle treated group. Treatment with ST ME (100 and 300 mg/kg, p.o.) and ST HOH (100 and 300 mg/kg, p.o.) and Vitamin C (0.3 mg/kg, p.o.) caused a significant ( $p < 0.05$ ) decrease in percentage change in body weight as compared to MSG-treated group

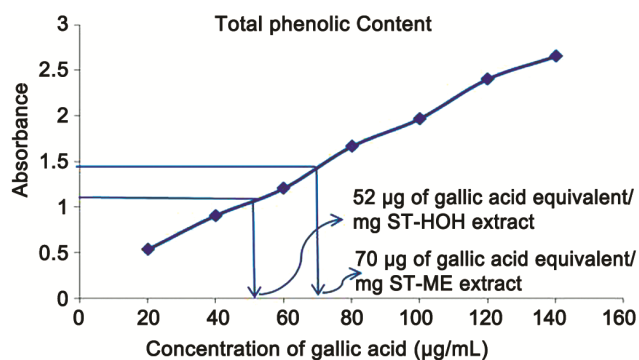


Fig. 2 — Total phenolic content determination ST-ME and ST-HOH extracts by Folin-Ciocalteu's method.

(Table.1). The increase in weight caused MSG has been ameliorated with *S. torvum* extracts.

#### Relative organ weight

There was a significant ( $p < 0.05$ ) increase in relative organ weight of liver and kidney tissue in rats given MSG treatment as compared to vehicle treated group. Treatment with ST ME (300 mg/kg, p.o.) and ST HOH (300 mg/kg, p.o.) and Vitamin (0.3 mg/kg, p.o.) caused a significant ( $p < 0.05$ ) decrease in relative organ weight of liver and kidney tissues compared to MSG-treated group (Table.1).

#### In vivo antioxidant parameters

Increase in LPO levels and decrease in SOD level is a mark of oxidative stress.

#### LPO activity

In our study, LPO activity showed a significant ( $p < 0.05$ ) increase in MSG (1000 mg/kg) treated the group as compared to the vehicle treated group. Treatment with Vitamin C (0.3 mg/kg, p.o), ST-ME (100 and 300 mg/kg, p.o.) and HOH (100 and 300 mg/kg, p.o.) significantly reduced LPO activity of liver and kidney tissue as compared to MSG-treated group (Table 2).

Table 1 — Effect of *S. torvum* on Monosodium glutamate-induced changes in percentage body weight, relative organ weight in Wistar rats.

Treatment Group (mg/kg)	Percentage change in body weight	Relative organ weight of Liver (g)	Relative organ weight of Kidney (g)
Control (10 mL/kg)	3.84±0.92	3.44±0.17	0.33±0.008
MSG (1000)	6.0±0.20 <sup>#</sup>	4.55±0.30 <sup>#</sup>	0.51±0.047 <sup>#</sup>
Vit-C (0.3) + MSG (1000)	3.08±0.60*	4.07±0.20	0.37±0.027*
ST-ME (100) + MSG (1000)	4.4±0.70*	4.07±0.18	0.45±0.020*
ST-ME (300) + MSG (1000)	3.24±0.52*	3.61±0.42*	0.39±0.014*
ST-HOH (100) + MSG (1000)	4.96±0.42*	4.38±0.29	0.46±0.062*
ST-HOH (300) + MSG 1000	4.34±0.85*	3.81±0.096*	0.41±0.011*

All values are expressed as mean±SEM. Statistical analysis was done using one-way analysis of variance, followed by Dunnett's multiple comparison tests. \* $p < 0.05$  was considered significant as compared to MSG group, <sup>#</sup> $p < 0.05$  was considered significant as compared to control.

MSG=Monosodium glutamate, ST-ME= Methanolic extract of *S. torvum*, ST-HOH= Hydroalcoholic extract *S. torvum*.

Table 2 — Effect of *S.torvum* on Monosodium glutamate-induced changes on anti-oxidant status in the liver and kidney tissue in Wistar rats.

Treatment Group (mg/kg)	LPO (Liver)(nMoles/ mg of wet tissue)	SOD (Liver) (U/mg of wet tissue)	LPO (Kidney) (nMoles/ mg of wet tissue)	SOD(Kidney) (U/mg of wet tissue)
Control (10 mL/kg)	12.20±3.17	35.57±8.31	7.57 ±1.61	49.14 ±3.76
MSG (1000)	118.7 ± 11.2 <sup>#</sup>	1.61 ± 0.24 <sup>#</sup>	87.44 ±8.47 <sup>#</sup>	3.06 ± 0.46 <sup>#</sup>
Vit-C(0.3) + MSG (1000)	34.58±1.26*	13.91 ±1.67*	26.4 ± 1.56*	16.54 ±2.64*
ST-ME (100) + MSG (1000)	37.79±1.53*	7.61± 0.34*	36.99 ± 2.33*	20.23±2.40*
ST-ME (300) + MSG (1000)	25.44±1.82*	27.08 ± 2.86*	16.81 ± 1.95*	40.51±2.71*
ST-HOH (100) + MSG (1000)	61.34±5.28*	5.02± 0.57*	46.32±4.07*	14.15±1.01*
ST-HOH (300) + MSG 1000	32.31±4.15*	20.86 ± 2.48*	25.5±2.72*	34.62±1.53*

All values are expressed as mean ± SEM. Statistical analysis was done using one-way analysis of variance, followed by Dunnett's multiple comparison tests. \* $p < 0.05$  was considered significant as compared to MSG group, <sup>#</sup> $p < 0.05$  was considered significant as compared to control. MSG=Monosodium glutamate, ST-ME= Methanolic extract of *S. torvum*, ST-HOH= Hydroalcoholic extract *S.torvum*.

**SOD activity**

There was a significant ( $p < 0.05$ ) decrease in SOD activity in rats given MSG treatment as compared to vehicle treated group. Treatment with ST-ME and ST-HOH (100 and 300 mg/kg, p.o.) caused a significant ( $p < 0.05$ ) increase in SOD activity. Vitamin C (0.3 mg/kg, p.o.) significantly ( $p < 0.05$ ) increased SOD activity of liver and kidney tissue as compared to MSG-treated group (Table 2).

**Biochemical Assays****Liver Function tests****ALT and AST levels**

There was a significant ( $p < 0.05$ ) increase in ALT and AST levels in MSG (1000mg/kg) treated the group as compared to vehicle treated group. Treatment with ST-ME (100 and 300 mg/kg,p.o.) and ST-HOH (300 mg/kg, p.o.) caused a significant ( $p < 0.05$ ) decrease in ALT and AST levels as compared to MSG-treated group (Table 3).

**ALP, Total protein and Albumin levels**

A significant ( $p < 0.05$ ) decrease in ALP levels, total protein activity and albumin levels were found in MSG (1000 mg/kg) treated group as compared to the vehicle treated group, whereas treatment with ST-ME (100 and

300 mg/kg, p.o.) caused a significant ( $p < 0.05$ ) increase in ALP level, total protein and albumin activity, as compared to MSG-treated group (Table 3).

**Bilirubin****Total Bilirubin and direct bilirubin**

A significant ( $p < 0.05$ ) increase in total and direct bilirubin activity in rats given MSG (1000 mg/kg) treatment was observed as compared to vehicle treated group, whereas, treatment with ST-ME(100 and 300mg/kg,p.o.) ST-HOH (100and 300mg/kg,p.o.) caused a significant ( $p < 0.05$ ) decrease in total and direct bilirubin(Table 3).

**Kidney Function tests****Urea and Creatinine**

There was a significant ( $p < 0.05$ ) decrease in urea levels and a significant ( $p < 0.05$ ) increase in creatinine level in rats given MSG (1000 mg/kg) as compared to vehicle treated group. Treatment with ST-ME (300mg/kg,p.o.) and ST-HOH (300 mg/kg, p.o.) caused a significant ( $p < 0.05$ ) increase in urea levels and significant ( $p < 0.05$ ) decrease in creatinine level (Table 4).

**Histopathological examination**

Histopathology studies of H&E stained liver sections of the MSG-treated group (Plate 1) showed

Table 3 — Effect of *S.torvum* on Monosodium glutamate-induced changes in Liver function tests in Wistar rats.

Treatment Group (mg/kg)	ALT (U/L)	AST (U/L)	ALP (U/L)	Protein (g/dL)	Albumin (g/dL)	Bilirubin (g/dL)	
						Total	Direct
Control (10 mL/kg)	33.15±4.82	23.79±2.75	51.67±8.06	9.00±2.71	5.96±1.74	13.35±3.61	11.77±2.44
MSG (1000)	112±12.13 <sup>#</sup>	77.33±1.28 <sup>#</sup>	5.50±0.84 <sup>#</sup>	0.847±0.13 <sup>#</sup>	0.29±0.03 <sup>#</sup>	148.6±6.34 <sup>#</sup>	140.6±10.48 <sup>#</sup>
Vit-C + MSG (1000)	73.98±13.27	42.13±2.61*	22.59±3.24*	5.11±0.49*	2.97±0.92*	20.43±8.82*	28.19±6.17*
ST-ME (100) + MSG (1000)	79.03±4.53*	71.35±3.64	17.27±0.23*	4.16±0.11*	1.64±0.12*	55.73±17.03*	38.17±6.94*
ST-ME (300) + MSG (1000)	44.44±1.77*	36.2±2.84*	35.24±6.55*	7.14±1.23*	3.24±0.33*	20.75±3.04*	21.75±4.07*
ST-HOH (100) + MSG (1000)	90.63±3.01	66.74±2.08*	12.1 ±1.60	1.78±0.12*	1.40±0.33*	57.25±9.82*	46.57±13.78*
ST-HOH (300) + MSG (1000)	63.87±2.44*	28.43±3.47*	27.43 ±4.02	5.5±0.28*	2.75±0.57*	26.51±2.32*	30.46±4.98*

All values are expressed as mean ± SEM. Statistical analysis was done using one-way analysis of variance, followed by Dunnett's multiple comparison tests. \* $p < 0.05$  was considered significant as compared to MSG group, # $p < 0.05$  was considered significant as compared to control.

MSG=Monosodium glutamate, ST-ME= Methanolic extract of *S. torvum*, ST-HOH= Hydroalcoholic extract *S. torvum*.

Table 4 — Effect of *S.torvum* on Monosodium glutamate induced changes in Kidney function tests of Wistar rats.

Treatment Group (mg/kg)	Urea (mg/100 mL)	Creatinine (mg/100 mL)
Control (10 mL/kg)	25.97±5.99	0.51±0.17
MSG (1000)	7.76±1.24 <sup>#</sup>	37.22±5.67 <sup>#</sup>
Vit-C + MSG (1000)	14.65±1.68*	3.75±0.91*
ST-ME (100) + MSG (1000)	9.06±0.88	2.30±0.83*
ST-ME (300) + MSG (1000)	17.5±2.15*	1.05±0.19*
ST-HOH (100) + MSG (1000)	8.51±2.03	7.59±0.60*
ST-HOH (300) + MSG (1000)	16.44±2.44*	1.72±0.31*

All values are expressed as mean ± SEM. Statistical analysis was done using one-way analysis of variance, followed by Dunnett's multiple comparison tests. \* $p < 0.05$  was considered significant as compared to MSG group, # $p < 0.05$  was considered significant as compared to control.

MSG=Monosodium glutamate, ST-ME= Methanolic extract of *S. torvum*, ST-HOH= Hydroalcoholic extract *S.torvum*.



centrilobular cytoplasmic vacuolations, sinusoidal congestion, oedema of hepatocytes, nuclear pyknosis, nuclear polymorphism, cellular aggregates of lymphocytes and macrophages around the portal area as compared to control group (Plate 2). Kidney sections of MSG-treated group (Plate 3) showed normal distortion of cortical structures, cell necrosis, vacuolation of

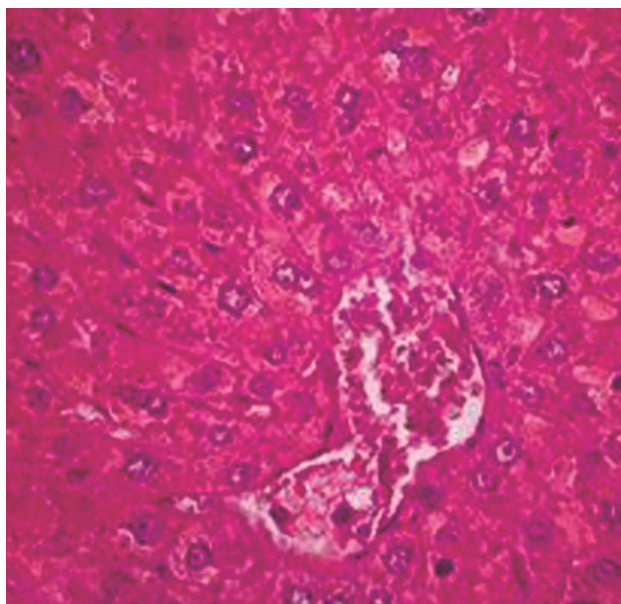


Plate 1 — Section of MSG-treated rat liver tissue (40X) showing centrilobular cytoplasmic vacuolations, sinusoidal congestion, oedema of hepatocytes, mild nuclear pyknosis, nuclear polymorphism, cellular aggregates of lymphocytes and macrophages around the portal area.

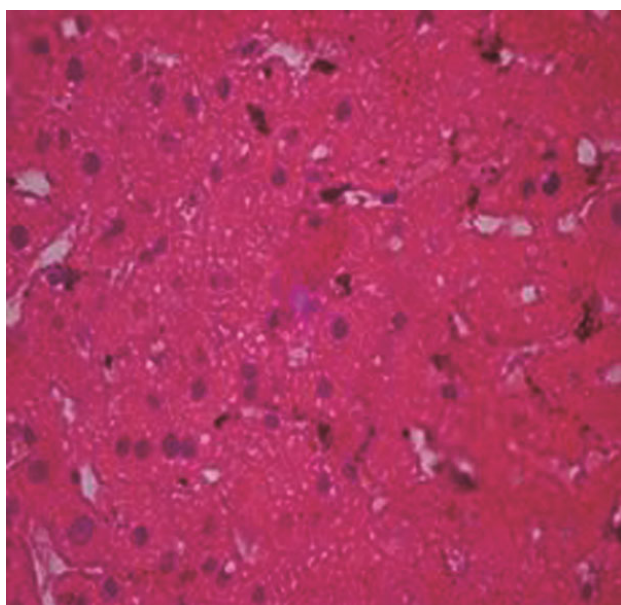


Plate 2 — Section of H&E stained control group rat Liver showing normal layers of the liver (40X).

stroma, tubular degeneration changes and atrophic changes as compared to control group (Plate 4). *Solanum torvum* and Vitamin C treatment in rats have shown to ameliorate the above pathological effects (Plate 5-9) and Plate 10-14, respectively)

### Discussion

The current study has explored the protective effects of a well-known herbal medicine *Solanum torvum* on the

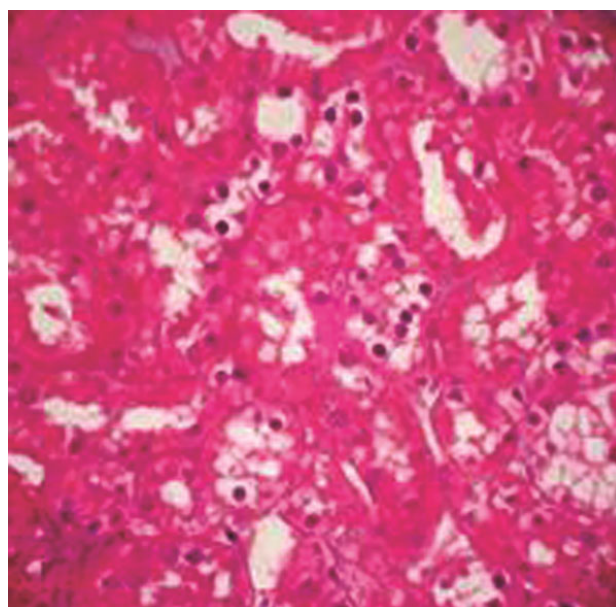


Plate 3 — Section of MSG-treated rat Kidney tissue (40X) showing distortion of cortical structures, cell necrosis, vacuolation of stroma, tubular degeneration changes and mild atrophic changes.

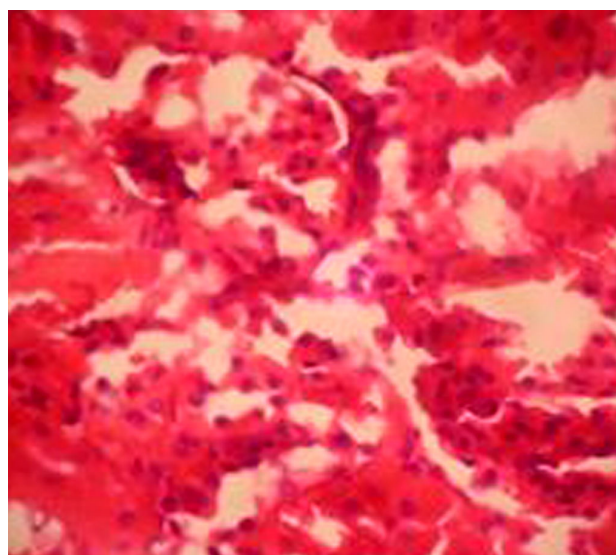


Plate 4 — Section of H&E stained control group rat kidney showing normal layers of the kidney (40X).



monosodium glutamate-induced hepatotoxicity and nephrotoxicity in Wistar rats through its morphological, biochemical and histopathological studies. Similar findings were reported in previous studies<sup>53,54</sup>.

Percentage change in body weight, relative organ weight of liver and kidney in MSG-treated rat was significantly increased which showed the toxic effect of MSG, while treatment with *S. torvum* significantly decreased the percentage body weight, relative organ weight of liver and kidney in MSG-treated a rat. Absolute organ weight and relative organ weight determination are commonly used tools in toxicity,

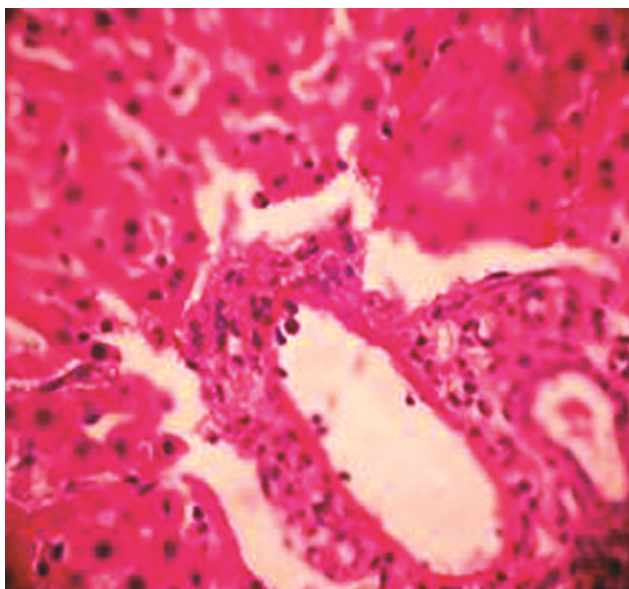


Plate 5 — Section of Vitamin C (300 mg/kg) and MSG-treated rat liver tissue (40X) showing mild sinusoidal congestion, nuclear polymorphism, nuclear pyknosis, cellular aggregates of lymphocytes and macrophages around the portal area.

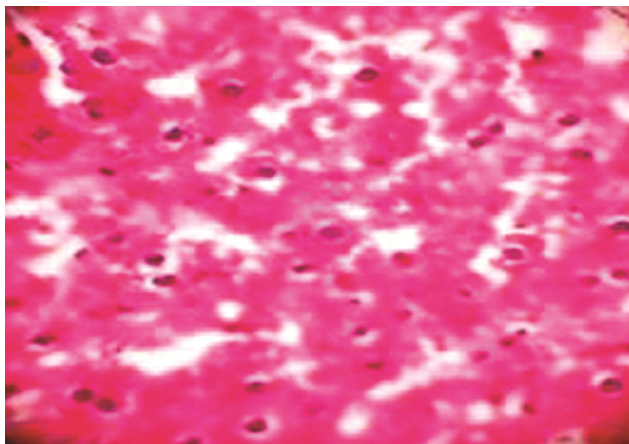


Plate 6 — Section of ST-ME (100 mg/kg) and MSG-treated rat liver tissue (40X) showing mild centrilobular cytoplasmic vacuolation, sinusoidal congestion, nuclear pyknosis, cellular aggregates of lymphocytes and macrophages around the portal area.

while the purpose of relative organ weight analysis is to detect any direct treatment effect on the organ weight over and above any indirect effect caused by the

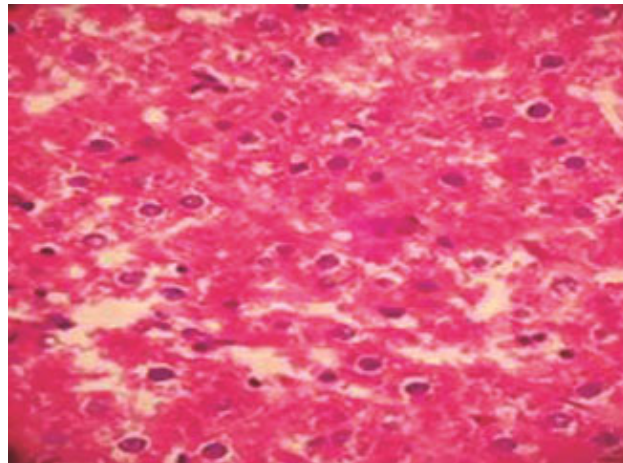


Plate 7 — Section of ST-ME (300 mg/kg) and MSG-treated rat liver tissue (40X) showing mild sinusoidal congestion.

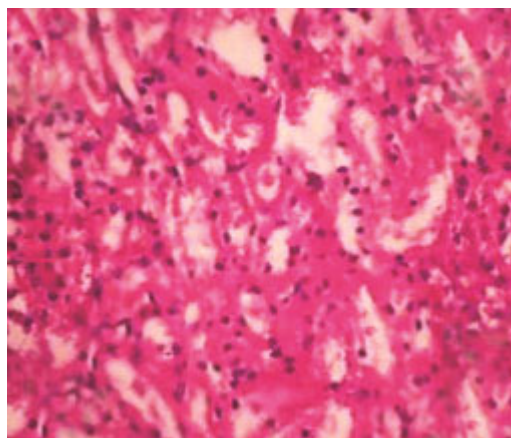


Plate 8 — Section of ST-HOH (100 mg/kg) and MSG-treated rat liver tissue (40X) showing mild centrilobular cytoplasmic vacuolation, sinusoidal congestion, nuclear pyknosis, nuclear polymorphism.

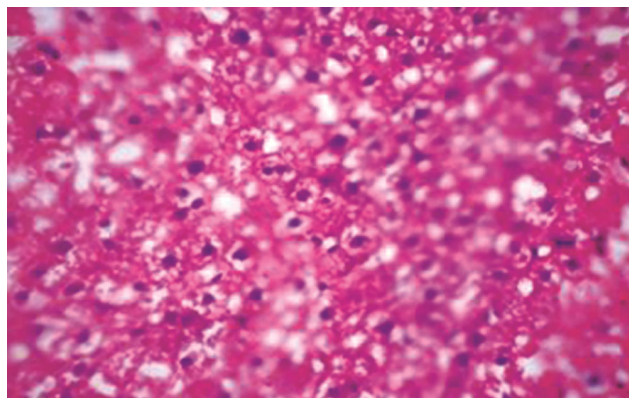


Plate 9 — Section of ST-HOH (300 mg/kg) and MSG-treated rat liver tissue (40X) showing normal layers of liver.



effects of the treatment on body weight<sup>55</sup>. Several hepatic and renal marker enzymes are used to access any toxicities associated with these organs. Hepatic marker enzymes include ALT, AST, alkaline phosphatase, serum protein, serum bilirubin and serum albumin, while renal marker enzymes are serum urea and serum creatinine. In addition to this antioxidant status of renal and hepatic tissue were used to determine any toxic stress faced by these organs.

Increase in lipid peroxidation in renal and liver tissue of the MSG-treated rats indicates increased damage due to peroxides to the lipid membranes of cells. This results in an increase in membrane permeability, destruction of cell surface receptors and ligands for vital messengers causing toxic effects and

decreased functions of the renal and hepatic cells<sup>56</sup>. While treatment with Vit-C and *Solanum torvum* extracts showed the significant protective effect by decreasing the lipid peroxidation in the kidney and liver. Superoxide dismutase enzyme is the first line protective mechanism responsible for the protection of cell from reactive oxygen species (ROS). A decline in functions of these enzymes in kidney and liver tissue of MSG-treated rats may be due to an imbalance in the redox system in the favour of oxidants than defence mechanism<sup>57</sup>. Treatment with Vit-C and *S. torvum* extracts showed the significant shifting of the redox system in favour of oxidative defence mechanism and has shown to be protective against stressed conditions.

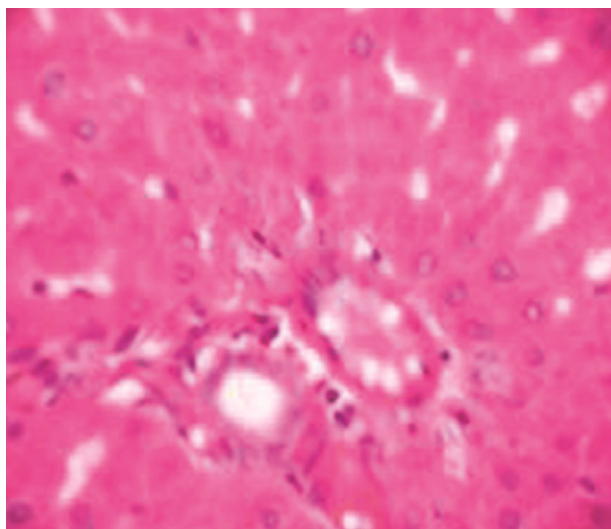


Plate 10 — Section of Vit-C (300 mg/kg) and MSG-treated rat Kidney tissue (40X) showing mild vacuolation of stroma

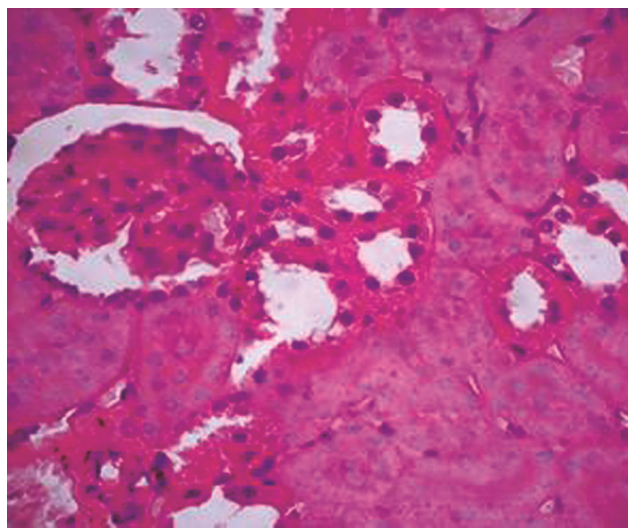


Plate 12 — Section of ST-ME (300 mg/kg) and MSG-treated rat Kidney tissue (40X) showing mild vacuolation of stroma, tubular degeneration changes.

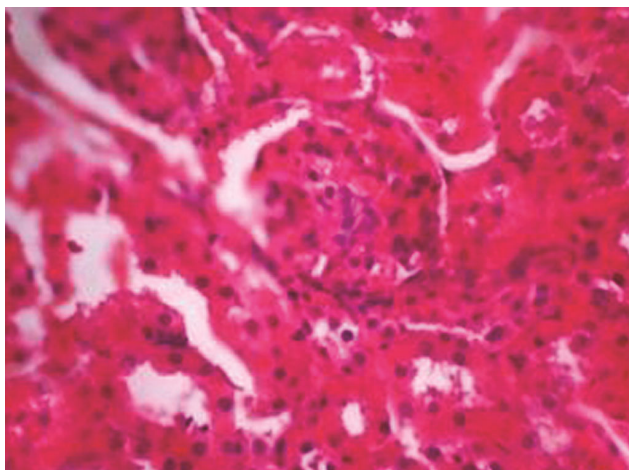


Plate 11 — Section of ST-ME (100 mg/kg) and MSG-treated rat Kidney tissue (40X) showing, vacuolation of stroma, tubular degeneration changes.

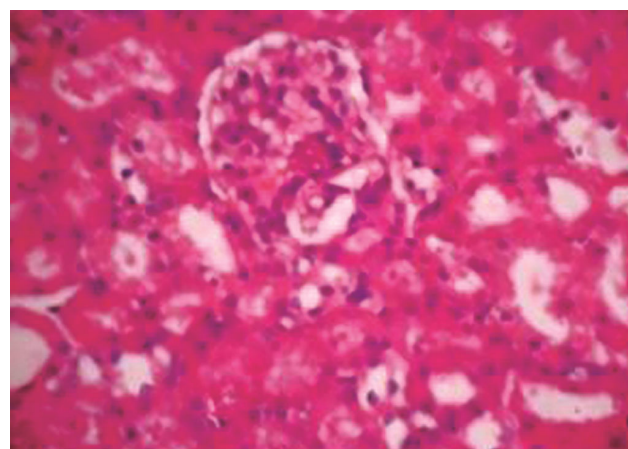


Plate 13— Section of ST-HOH (100 mg/kg) and MSG-treated rat Kidney tissue (40X) showing, vacuolation of stroma, tubular degeneration changes and mild cell necrosis.

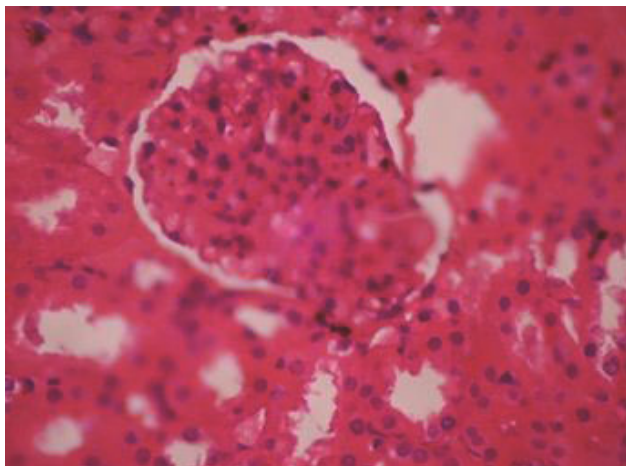


Plate 14 — Section of ST-HOH (300 mg/kg) and MSG-treated rat Kidney tissue (40X) showing mild vacuolation of stroma, tubular degeneration changes.

Changes in liver marker enzymes like an increase in activity of ALT and AST, decrease in activity of alkaline phosphatase in MSG-treated mice are indicators of hepatic dysfunction as compared to control group animals, other biomarkers like bilirubin (direct and total), serum protein, serum albumin have shown significant changes in MSG-treated rats<sup>28</sup>. While treatment with Vit-C and *S. torvum* extracts significantly protects MSG-induced hepatic damage.

Serum urea and serum creatinine are two major markers of renal function. Urea and creatinine are excretory products formed in the body and need to be excreted through urine. Deficiency in renal function may lead to decreased clearance of urea and creatinine and accumulation of these excretory products in the circulation<sup>58</sup>. There is a significant increase in serum urea and creatinine in MSG-treated group as compared to control due to renal deficiency, while treatment with *S. torvum* extracts significantly increased the clearance of urea and creatinine.

The histopathological changes induced by MSG were reversed with treatment of *S. torvum*. Treatment with *S. torvum* showed significant hepatoprotective and nephroprotective activity against Monosodium glutamate-induced hepatotoxicity and nephrotoxicity.

### Conclusion

*S. torvum* extracts have the potential to attenuate MSG-induced hepatic and renal damage in Wistar rats.

### Acknowledgement

Authors are thankful to the Mr. Pradeep Vader, Lab Technician for assisting with the histopathology

studies and Dr. Parkash Gadhi for interpretation of histopathological data. We also acknowledge Orchid Scientific and Innovative India Pvt Ltd, Ambad for their assistance in enriching our laboratory facilities.

### Conflict of interest

The authors have no conflict of interest.

### References

- Wallace A H, Principle and method of toxicology, *Race & Press*, 1982, 1-26.
- Eweka A O, Igbigbi P S and Ucheya RE, Histochemical Studies of the effect of Monosodium glutamate on the Liver of Adult Wistar Rats, *Ann Med Health Sci Res*, 2011, **1**(1), 21-29.
- Beyreuther K, Biesalski H K, Fernstrom J D *et al.*, Consensus meeting: monosodium glutamate-an update, *Eur J Clin Nutr*, 2007, **61**(3), 304-313.
- Williams A N, Woessner K M, Monosodium glutamate 'allergy': menace or myth?, *Clin Exp Allergy*, 2009, **39**(5), 640-646.
- Adrienne S, The toxicity of MSG, a study in suppression of Information, *Accountability Res*, 1999, **6**(4), 259- 310.
- Husarova V and Ostatnikova D, Monosodium glutamate toxic Effects and their Implications for Human Intake: A Review, *J Med Research*, 2013, **2013**, 1-12.
- IFIC, International Food Information Council Foundation, 1994, 1-11.
- Ikeda K, New seasonings, *Chem senses*, 2002, **27**(9), 847-849.
- Schaumburg H H, Byck R, Gerstl R and Mashman J H, Monosodium L-glutamate: its pharmacology and role in the Chinese restaurant syndrome, *Science*, 1969, **163**, 826-828.
- Park C H, Choi S H, Piao Y, Kim S H, Lee Y J, *et al.*, Glutamate and aspartate impair memory retention and damage hypothalamic neurons in adult mice, *Toxicol Lett*, 2000, **115**(2), 117-125.
- Gobatto C A, Mello M A, Soueza C T and Ribeiro I A, The monosodium glutamate (MSG) obese rat as a model for the study of exercise in obesity, *Res Commun Mol Pathol Pharmacol*, 2002, **111**(1-4), 89-101.
- Praputpittaya C and Wililak A, Visual Performance in Monosodium Glutamate-Treated Rats, *Nutr Neurosci*, 2003, **6**(5), 301-307.
- Geha R S, Beiser A, Ren C, Patterson R, Greenberger P A, *et al.*, Review of alleged reaction to monosodium glutamate and outcome of multicenter double blind placebo- controlled study, *J Nutr*, 2000, **130**(4), 1058-1062.
- Schwartz J R, In bad taste, the MSG "syndrome" MSG, Annual conference of the weston a price foundation, 5<sup>th</sup> Edn, 2004.
- Johnson P J, The Assessment of hepatic function and investigation of Jaundice, *Clin Biochem, Metabolic and Clin Aspects*, Churchill Livingstone, New York, 1995, 217-236.
- Khaidakov M, Bishop M E, Manjanatha M G, Lyn-Cook L E, Desai V G, *et al.*, Influence of dietary antioxidants on mutagenicity of 7, 12-dimethylbenz [a] anthracene and bleomycin in female rats, *Mutat Res*, 2001, **480-481**, 163-170.

- 17 Adjanohoun J E, Aboubakar N, Dramane K, Ebot M E, Ekpere J E, *et al.*, Traditional medicine and pharmacopeia contribution to ethnobotanical and floristic studies in Cameroon In: CNPMS. Porto- Novo, Benin, 1996, 50-52.
- 18 Siemonsma J S and Jansen P C M, *Solanum americanum* Merrill, In: J S Siemonsma and K. Piluek (Eds.), Plant Resources of South-East Asia, 1994, **8**, 252-255.
- 19 Ajaiyeoba E O, Comparative phytochemical and antimicrobial studies of *Solanum macrocarpum* and *S. torvum* leaves, *Fitoterapia*, 1999, **70**(2), 184-186.
- 20 Chah K F, Muko K N and Oboegbulem S I, Antimicrobial activity of methanolic extract of *Solanum torvum* fruit, *Fitoterapia*, 2000, **71**(2), 187-189.
- 21 Arthan D, Svasti J, Kittakoop P, Pittayakhachonwut D, Tanticharoen M, *et al.*, Antiviral isoflavonoid sulfate and steroidal glycosides From the fruits of *Solanum torvum*. *Phytochem*, 2002, **59**(4), 459-463.
- 22 Israif D A, Lajis N H, Somchit M N and Sulaiman M R, Enhancement of ovalbumin-specific IgA responses via oral boosting with antigen co-administered with an aqueous *Solanum torvum* extract, *Life Sci*, 2004, **75**(4), 397-406.
- 23 Nguelefack T B, Feumebo C B, Ateufack G, Watcho P, Tatsimo S, *et al.*, Anti- ulcerogenic properties of the aqueous and methanol extracts from the leaves of *Solanum torvum* Swartz (Solanaceae) in rats, *J Ethnopharmacol*, 2008, **119**(1), 135-140.
- 24 Sivapriya M and Srinivas L, Isolation and purification of a novel antioxidant protein from the water extract of Sundakai (*Solanum torvum*) seeds, *Food Chem*, 2007, **104**(2), 510-517.
- 25 Kannan M, Dheeba B, Gurudevi S and Ranjit Singh A J A, Phytochemical, antibacterial and antioxidant studies on medicinal plant *Solanum torvum*, *J Pharm Res*, 2012, **5**(5), 2418-2421.
- 26 Ndebia E J, Kamgang R and Nkeh-chungag Anye B N, Analgesic and anti-inflammatory properties of aqueous extract from leaves of *Solanum torvum* (Solanaceae), *Afr J Trad, Comp and Alt Med*, 2007, **4**(2), 240-244.
- 27 Kamble S, Mohan M and Kasture S, Protective Effect of *Solanum torvum* on doxorubicin-induced cardiotoxicity in rats, *Pharmacologyonline*, 2009, **2**, 1192-1204.
- 28 Mohan M, Kamble S, Satyanarayana J, Nageshwar M and Reddy N, Protective effect of *Solanum torvum* on doxorubicin- induced hepatotoxicity in rats, *Int J Drug Dev Res*, 2011, **3**(3), 131-138.
- 29 Mohan M, Kamble S, Gadhi P and Kasture S, Protective effect of *Solanum torvum* on doxorubicin-induced nephrotoxicity in rats, *Food Chem Toxicol*, 2010, **48**(1), 436-440.
- 30 Mohan M, Jaiswal B S and Kasture S, Effect of *Solanum torvum* on blood pressure and metabolic alterations in fructose hypertensive rats, *J Ethnopharmacol*, 2009, **126**(1), 86-89.
- 31 Peranginangin J M, Soemardaji A A, Ketut A J and Diah D, Therapeutic potency of *Solanum torvum* Swartz on benign prostatic hyperplasia treatment: A review, *Int J Res Phytochem Pharmacol*, 2013, **3**(3), 121-127.
- 32 Cuervo A C, Blunden G and Patel A V, Chlorogenone and neochlorogenone from the unripe fruits of *Solanum torvum*, *Phytochem*, 1991, **30**(4), 1339-1341.
- 33 Yahara S, Yamashita T, Nozawa N and Nohara T, Steroidal glycosides from *Solanum torvum*, *Phytochem*, 1996, **43**(5), 1069-1074
- 34 Yuan-Yuan L U, Jian-Guang L U O, Ling-Yi Kong, Chemical constituents from *Solanum torvum*, *Chin J Nat Med*, 2011, **9**(1), 30-32.
- 35 Perez-Amador M C, Ocotero V M, Castaneda J M G and Esquinca A R G, Alkaloids in *Solanum torvum* Sw (Solanaceae), *Int J Exp Bot*, 2007, **76**, 39-45.
- 36 Hwang S L, Shih P H and Yen G C, Neuroprotective effect of citrus flavonoids, *J Agric Food Chem*, 2012, **60**(4), 877-85.
- 37 Eweka A O, Histological studies of the effects of monosodium glutamate on the kidney of adult wistar rats, *Internet J Health*, 2006, **6**(2), 1-6.
- 38 Inuwa H M, Aina V O, Baba Gabi, Ola I A and Ja'afaru L, Determination of nephrotoxicity and hepatotoxicity of monosodium glutamate (MSG) Consumption, *Br J Pharmacol Toxicol*, 2011, **2**(3), 148-153.
- 39 Tawfik M S and Al-Badr N, Adverse effects of monosodium glutamate on liver and kidney functions in adult rats and potential protective effect of vitamins C and E, *Food Nutr Sci*, 2012, **3**, 651-659.
- 40 Brosnan M E and Brosnan J T, Hepatic glutamate metabolism: a tale of 2 hepatocytes, *Am J Clin Nutr*, 2009, **90**(3), 857S-861S.
- 41 Nakanishi Y, Tsuneyama K, Fujimoto M, Salunga T L, Nomoto K, *et al.*, Monosodium glutamate (MSG): a villain and promoter of liver inflammation and dysplasia, *J Autoimmun*, 2008, **30**(1-2), 42-50.
- 42 Husarova V and Ostatnikova D, Monosodium glutamate toxic effects and their implications for human intake: A review, *J Med Research*, 2013, **2013**, 1-12.
- 43 Singleton V L, Orthofer R and Lamuela-Raventós R M, Analysis of total phenols and other oxidation substrates and antioxidants by means of folin-ciocalteu reagent, *Methods Enzymol*, 1999, **299**, 152-178.
- 44 Stankovic M S, Total phenolic content, flavonoid concentration and antioxidant activity of *marrubium peregrinum* L. extracts, *Kragujevac J Sci*, 2011, **33**, 63-72.
- 45 Saggi H, Cooksey J, Dexter D, Wells F R, Lees A, *et al.*, A selective increase in particular superoxide dismutase activity in parkinsonian substantia nigra, *J Neurochem*, 1989, **53**(3), 692-697.
- 46 Niehaus W G and Samuelsson B, Formation of malonaldehyde from phospholipids arachidonate during microsomal lipid peroxidation, *Eur J Biochem*, 1968, **6**(1), 126-130.
- 47 Turan S, Topcu B, Gokce I, Guran T, Atay Z, *et al.*, Serum alkaline phosphatase levels in healthy children and evaluations of alkaline phosphatase-scores in different types of rickets, *J Clin Res Pediatr Endocrinol*, 2011, **3**(1), 7-11.
- 48 Johnsan A M, Rohlf E M and Silverman L M, Proteins In: Burtis CA Ashwood ER editors. *TIETZ Textbook of clinical chemistry*, 3<sup>rd</sup> ed Philadelphia, WB Saunders Company, 1999, 477-540.
- 49 Haslam and Ruth M, (Association of Clinical Biochemist), Determination of Urea by Auto Analyzer, Technical Bulletin, 1993.
- 50 Bowers L D, Kinetic serum creatinine assays I. The role of various factors in determining specificity, *Clin Chem*, 1980, **26**(5), 551-554.
- 51 Palipoch S and Punsawad C, Biochemical and histological study of rat liver and kidney injury induced by cisplatin, *J Toxicol Pathol*, 2013, **26**(3), 293-299.



- 52 Kasture S B, A Handbook of experiments in pre-clinical pharmacology, 1<sup>st</sup> ed., Career publication, 2006.
- 53 Onyema O O, Farombi E O, Emerole G O, Ukoha A I and Onyeze G O, Effect of vitamin E on monosodium glutamate induced hepatotoxicity and oxidative stress in rats, *Indian J Biochem Biophys*, 2006, **43**(1), 20-24.
- 54 Elatrash A M and El-Haleim S Z A, Protective role of *Ginkgo biloba* on monosodium glutamate: Induced liver and kidney toxicity in rats, *Res J Pharm Biol Chem Sci*, 2015, **6**(1), 1433-1441.
- 55 Shirley E, The analysis of organ weight data, *Toxicol*, 1977, **8**(1), 13-22.
- 56 Poli G, Albano E and Dianzani M U, The role of lipid peroxidation in liver damage, *Chem Phys Lipids*, 1987, **45** (2-4), 117-142.
- 57 Young I S and Woodside J V, Antioxidants in health and disease, *J Clin Pathol*, 2001, **54**, 176-186.
- 58 Kim S Y and Moon A, Drug-Induced nephrotoxicity and Its biomarkers, *Biomol Ther*, 2012, **20**(3), 268-272.